

Physical Therapy

Journal of the American Physical Therapy Association and



de Fysiotherapeut

Royal Dutch Society for Physical Therapy



Scapular Muscle Exercises Following Neck Dissection Surgery for Head and Neck Cancer: A Comparative Electromyographic Study

Aoife C. McGarvey, Peter Grant Osmotherly, Gary R. Hoffman and Pauline E. Chiarelli

PHYS THER. 2013; 93:786-797.

Originally published online February 21, 2013

doi: 10.2522/ptj.20120385

The online version of this article, along with updated information and services, can be found online at: <http://ptjournal.apta.org/content/93/6/786>

Collections

This article, along with others on similar topics, appears in the following collection(s):

[Cancer](#)

[Injuries and Conditions: Neck](#)

[Injuries and Conditions: Shoulder](#)

[Kinesiology/Biomechanics](#)

[Therapeutic Exercise](#)

e-Letters

To submit an e-Letter on this article, click [here](#) or click on "Submit a response" in the right-hand menu under "Responses" in the online version of this article.

E-mail alerts

Sign up [here](#) to receive free e-mail alerts

Scapular Muscle Exercises Following Neck Dissection Surgery for Head and Neck Cancer: A Comparative Electromyographic Study

Aoife C. McGarvey, Peter Grant Osmotherly, Gary R. Hoffman, Pauline E. Chiarelli

A.C. McGarvey, BAppSc(Physiotherapy), Physiotherapy Department, Calvary Mater Newcastle Hospital, Newcastle, New South Wales, Australia, and School of Health Sciences, Faculty of Health, University of Newcastle, Callaghan, New South Wales, Australia. Mailing address: Physiotherapy Department, Calvary Mater Newcastle Hospital, Edith Street, Waratah, 2298, New South Wales, Australia. Address all correspondence to Ms McGarvey at: aoife.mcgarvey@calvarymater.org.au.

P.G. Osmotherly, MMedSc(Clinical Epidemiology), BSc, GradDip-Physiotherapy, School of Health Sciences, Faculty of Health, University of Newcastle.

G.R. Hoffman, MBBS, PhD, FACS, FRCS, School of Medicine, Faculty of Health, University of Newcastle, and John Hunter Hospital, New Lambton, New South Wales, Australia.

P.E. Chiarelli, PhD, MMedSc (HProm), DipPhysiotherapy, GradDipHSocSc(HProm), School of Health Sciences, Faculty of Health, University of Newcastle.

[McGarvey AC, Osmotherly PG, Hoffman GR, Chiarelli PE. Scapular muscle exercises following neck dissection surgery for head and neck cancer: a comparative electromyographic study. *Phys Ther*. 2013;93:786–797.]

© 2013 American Physical Therapy Association

Published Ahead of Print:
February 21, 2013

Accepted: February 10, 2013
Submitted: October 3, 2012

Background. Shoulder pain and dysfunction can occur following neck dissection surgery for cancer. These conditions often are due to accessory nerve injury. Such an injury leads to trapezius muscle weakness, which, in turn, alters scapular biomechanics.

Objective. The aim of this study was to assess which strengthening exercises incur the highest dynamic activity of affected trapezius and accessory scapular muscles in patients with accessory nerve dysfunction compared with their unaffected side.

Design. A comparative design was utilized for this study.

Methods. The study was conducted in a physical therapy department. Ten participants who had undergone neck dissection surgery for cancer and whose operated side demonstrated clinical signs of accessory nerve injury were recruited. Surface electromyographic activity of the upper trapezius, middle trapezius, rhomboid major, and serratus anterior muscles on the affected side was compared dynamically with that of the unaffected side during 7 scapular strengthening exercises.

Results. Electromyographic activity of the upper and middle trapezius muscles of the affected side was lower than that of the unaffected side. The neck dissection side affected by surgery demonstrated higher levels of upper and middle trapezius muscle activity during exercises involving overhead movement. The rhomboid and serratus anterior muscles of the affected side demonstrated higher levels of activity compared with the unaffected side.

Limitations. Exercises were repeated 3 times on one occasion. Muscle activation under conditions of increased exercise dosage should be inferred with caution.

Conclusions. Overhead exercises are associated with higher levels of trapezius muscle activity in patients with accessory nerve injury following neck dissection surgery. However, pain and correct scapular form must be carefully monitored in this patient group during exercises. Rhomboid and serratus anterior accessory muscles may have a compensatory role, and this role should be considered during rehabilitation.



Post a Rapid Response to
this article at:
ptjournal.apta.org

Cancer that develops in the head and neck is able to metastasize to the cervical lymph nodes. Neck dissection surgery is undertaken as part of the management of these cancers and involves removal of the relevant draining lymph nodes. The spinal accessory nerve is encountered during various types of neck dissection on its path to penetrate and supply the sternocleidomastoid and trapezius muscles. The accessory nerve is at operative risk from either a direct or indirect injury during several types of neck dissection, even if remaining macroscopically intact.¹ Such injuries result in a reduced motor input to, and therefore weakness of, the trapezius muscles. Dysfunction in these muscles is typified at rest by a dropped, winged, and medially rotated scapula. Dynamically, reduced scapular elevation and rotation motion results in decreased glenohumeral abduction and flexion, when the trapezius muscle is most active.² Abnormal scapular biomechanics cause mechanical overload to the shoulder joint complex, leading not only to reduced regional function but also to pain and negative effects on quality of life.³ Neck dissection has become increasingly focused on preserving the accessory nerve in an attempt to limit postoperative shoulder morbidity. Despite this trend, shoulder dysfunction has been reported in up to 67% of patients with a spared accessory nerve.¹ The high incidence of shoulder morbidity remains a pertinent and debilitating postoperative issue.

Physiologically, there is an argument for addressing this biomechanical dysfunction, by including strengthening exercises that maximize trapezius muscle activity, to subsequently improve scapular elevation and lateral rotation. Electromyography (EMG) is a tool that can be used to monitor muscle activity and, therefore, a method to aid exercise

selection. Strengthening exercises associated with the highest levels of upper and middle trapezius muscle activity measured through EMG are likely to be the most beneficial in patients experiencing trapezius muscle weakness resulting from accessory nerve injury.

Following neck dissection, patients may experience not only the direct impact of accessory nerve injury causing reduced trapezius muscle activity but also the sequelae of secondary scapular and glenohumeral muscle imbalances. As such, the term “accessory nerve shoulder dysfunction” (ANSND) is utilized to describe the overall observed muscle imbalances in this patient group.

The effectiveness of strengthening exercises for the trapezius muscle and other accessory scapular muscles has been studied using surface electromyography (SEMG) in individuals who were healthy.^{4,5} However, these studies examined participants

without either shoulder pain or restriction in shoulder movement. Patients experiencing ANSD after neck dissection are unlikely to have sufficient shoulder elevation movement to perform commonly recommended scapular strengthening exercises such as horizontal abduction, scaption,⁴ and bench press.⁵ Consequently, scapular strengthening exercises may need to be modified in order to be feasible for patients with ANSD. Which specific exercises are most effective, in terms of scapular muscle activity and particularly trapezius muscle activation, is unknown in the ANSD population.

Patients who develop ANSD frequently undergo postoperative radiation therapy and chemotherapy.⁶ Radiation therapy typically is directed over the lateral aspect of the neck, predisposing the patient to further demyelination of the accessory nerve neural sheath and causing fibrosis of the trapezius muscle.^{7,8}

The Bottom Line

What do we already know about this topic?

Neck dissection for cancer treatment is associated with injury to the accessory nerve, which causes weakness and reduced activity in the trapezius muscle and leads to shoulder pain and reduced regional function. Strengthening exercises may be prescribed in order to improve trapezius muscle weakness. The type of strengthening exercises that maximize trapezius muscle activity in patients with shoulder pain or restrictions in shoulder movement is unknown.

What new information does this study offer?

This study found that upper and middle trapezius muscle activity was greatest during strengthening exercises involving overhead movement.

If you're a patient, what might these findings mean for you?

To strengthen your shoulder muscles, your physical therapist may prioritize overhead strengthening exercises to increase the activity in this muscle group. Pain, however, must be avoided, and correct scapular form must be carefully monitored, during repeated overhead exercises.

Treatment of head and neck cancer often leads to loss of muscle mass resulting from significant weight loss.⁹ Cancer-related fatigue and reduced physical activity occur in as many as 50% of patients with head and neck cancer following treatment.¹⁰ This is a further factor compounding both muscle weakness and the capacity to exercise. Factors in patients with head and neck cancer, such as daily alcohol consumption, lower levels of education, radical neck dissection surgery, depression, and anxiety, also have been found to significantly reduce exercise adherence.¹¹ It is crucial for exercise selection to be maximized in patients with ANSD, given there are a multitude of factors reducing their overall capacity to exercise. Maximizing the impact of scapular muscle strengthening exercise selection is likely to augment effectiveness of rehabilitation in this patient group.

The effectiveness of progressive scapular muscle strengthening exercises has been investigated in patients with ANSD.¹² However, the exercises selected in that study consisted of general upper body strengthening, rather than targeted, biomechanically specific exercises. In addition, patients with accessory neurotmesis, which arguably would not benefit from strengthening exercises because the potential for trapezius muscle recovery is minimal,¹³ were included in the sample. Neither that study, nor any other examination of this patient group since, recorded the EMG activity of trapezius or accessory scapular muscles in patients following neck dissection surgery under dynamic conditions. Intramuscular needle EMG activity of the trapezius muscle has been used to explore accessory nerve conduction on the operated side after neck dissection.^{14–16} These studies have provided information regarding the levels of trapezius muscle activity in patients who are affected. How-

ever, when considering rehabilitation exercises, dynamic SEMG studies are likely to be more clinically informative in establishing those exercises associated with higher levels of trapezius muscle activity.

The primary aims of this study were: (1) to investigate which exercises suitable for prescription for patients with ANSD following neck dissection have the highest dynamic SEMG activity of the trapezius muscle and (2) to explore coexisting patterns of muscle activity in other scapular accessory muscles. A secondary aim was to assess any differences in relevant muscle activity between the affected and unaffected sides of the participants following neck dissection. Gaining an understanding of which exercises are associated with higher levels of trapezius muscle activity will maximize effective exercise selection by physical therapists in the rehabilitation of patients with ANSD following neck dissection. Insight into scapular muscle patterns in this patient population has potential to provide further specificity in directing rehabilitation.

Method

Participants

Participants who had undergone neck dissection surgery were recruited from the hospital via a letter of invitation. Written informed consent was obtained from all participants.

Participants were eligible for inclusion if they had: (1) neck dissection surgery for cancer within the previous 2 years; (2) shoulder pain on the operated side, with onset after neck dissection; (3) clinical signs of ANSD demonstrated on the operated side (scapular depression, reduced active shoulder abduction, and scapular winging at rest or on active shoulder abduction); (4) no previous experience with the exercises performed; and (5) age over 18 years. Potential

participants were excluded if they had: (1) accessory nerve sacrifice; (2) a history of shoulder or neck pain in the 6 months prior to neck dissection surgery; (3) signs of adhesive capsulitis (reduced shoulder external rotation, abduction, and internal rotation); (4) the presence of residual loco-regional cancer or distant metastases to other regions; or (5) a pre-existing medical condition with an inability to repeatedly lift a 2.0-kg weight or perform exercise against resistance. The aim of recruitment was to include 10 participants, which is comparable to sample sizes in other descriptive SEMG studies involving the shoulder.^{4,17}

Baseline participant characteristics recorded were sex, age, hand dominance, current occupation, date and type of neck dissection surgery, cancer location and staging, and whether radiation therapy or chemotherapy was administered following surgery.

Design

A comparative design was utilized for this study. Patients who had undergone neck dissection surgery and whose operated side demonstrated clinical signs of ANSD were the first group studied and were labeled the “neck dissection affected arm” (NDA) group. In a comparison group, the EMG activity of the muscles of the unaffected arm of the same participants was studied (NDU group). Bilateral scapular SEMG activity of the upper trapezius, middle trapezius, rhomboid major, and serratus anterior muscles was recorded. Assigned participant numbers ensured that all data were maintained in a de-identified form.

Procedure

Ten electrodes were placed over 4 muscles (active electrodes) and 2 bony prominences (reference electrodes), as summarized in Appendix 1. Electrode location was standard-

ized according to anatomical and SEMG human studies,^{18–20} and accepted procedures for SEMG sensor placement were followed²¹ to maximize reliability of the EMG data. All active electrodes were placed parallel to the muscle fibers. The inter-electrode distance for all active electrode placement points was 3.0 cm. One reference electrode was placed on the spinous process of seventh cervical vertebra, with the second reference electrode placed on the ipsilateral clavicle. Surface electrodes were connected to leads that linked to amplifiers. Collection of SEMG recordings was done using ADI Power Lab 8SP (ML 785) and 2 dual bioamplifiers (ML135) (ADInstruments Pty Ltd, Bella Vista, Australia).

Surface EMG signals were amplified and filtered with a low-pass filter of 50 Hz, with data acquired at a sampling rate of 2 kHz and a recording range of 0 to 2 mV. Raw EMG signals then were transmitted from the electrodes to a computer for processing (Lab Chart version 7 for Windows XP operating system) and storage for future analysis (Figure). Electromyographic data were collected simultaneously from the upper trapezius, middle trapezius, rhomboid, and serratus anterior muscles for each exercise performed. All raw EMG data were visually inspected during testing. If there was doubt as to the validity of EMG data recorded, or the signal had noise artifact, the exercise was repeated and labeled accordingly.

Participants were asked to perform a series of 7 sequentially ordered dynamic strengthening exercises with a 2.0-kg weight (Appendix 2), first with the affected arm (NDA group) and then with the unaffected arm (NDU group). Each exercise was performed in a standardized manner with maximum displacement taking place over a 3-second period followed by 3 seconds to

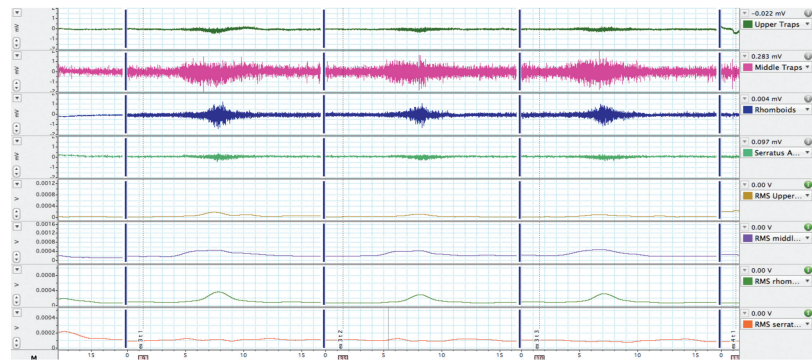


Figure.
Visual electromyographic display of muscle activity.

return to the starting position. Three repetitions were performed for each exercise, with at least a 30-second rest between repetitions and 60 seconds rest between different exercises. To maximize the correct performance of each exercise, practice occurred prior to testing, and visual and verbal feedback were given to the participants. If the exercise was incorrectly performed, the exercise was repeated, with feedback provided to correct the performance. If a participant experienced pain or was physically unable to correctly perform the exercise, the exercise was ceased and data were labeled “Participant unable to complete due to pain/inability to perform/incorrectly performed.” The trial then was excluded from subsequent data analysis.

Electrodes were removed from the rhomboid major muscle for exercise 7, as the exercise required participants to be positioned supine. Therefore, no data were collected for the rhomboid major muscle for exercise 7.

Data Reduction

All raw EMG data were filtered with a high-pass filter of 1 Hz, then smoothed using root mean square (RMS). A visual inspection of EMG data obtained was undertaken to maximize signal validity. All data

that included noisy signals were excluded. Noisy signals included artifacts such as electrocardiogram activity, movement error, and insufficient resting baseline EMG activity. For all 3 trials of each exercise, or those clean trials remaining, a 3-second total time period either side of the maximum raw RMS EMG activity was selected for subsequent numerical data analysis. The average RMS EMG of the trials was calculated for each of the 7 exercises to represent the mean muscle activity. The resultant data set consisted of raw RMS EMG averages for each dynamic exercise for each muscle.

Data Analysis

Data were compared in raw RMS format, as the data comparison was within-subjects. Additionally, participants had a painful condition that may have reduced their ability to perform a maximal voluntary contraction (MVC) for normalization purposes.²²

To examine differences between the NDA and NDU groups, a generalized linear mixed model was fitted to the data using STATA 12.0 statistical software (Stata Corp LP, College Station, Texas), with a level of significance set at $P < .05$. The outcome variable was EMG activity (in millivolts), and the main predictor was by group with a dummy variable for exercise

Scapular Muscle Exercises Following Neck Dissection Surgery

Table 1.

Baseline Characteristics of Participants^a

Participant No.	Sex	Age (y)	Tumor Site and Stage (TNM)	Radiation Therapy	Surgery Type (Levels Dissected)	Time Between Surgery and Assessment	Hand Dominance	Occupation
1	Male	60	T1N1M0 neck node	Yes	Right MRND (I–V)	10 wk	Right	Cleaner
2	Male	57	T2N1M0 mandible and floor of mouth	No	Bilateral MRND (I–V)	4 wk	Right	Unemployed
3	Male	61	T4N0M0 SCC ear	Yes	Left SND (I–IV)	8 wk	Right	Machinery inspector
4	Male	55	T4N0M0 SCC suborbital region	Yes	Right SND (I–IV)	13 mo	Right	Pest controller
5	Male	64	T1N0M0 oral tongue	No	Left SND (I–IV)	20 mo	Right	Retired
6	Male	57	N2M0 unknown primary metastatic SCC	No	Left SND (I–IV)	8 wk	Right	Teacher
7	Male	75	T2N0M0 SCC forehead	No	Left MRND (I–V)	7 wk	Left	Retired
8	Male	57	T4N0M0 SCC mandible	Yes	Bilateral SND (I–IV)	14 mo	Right	Retired
9	Female	62	T2N0M0 buccal SCC	Yes	Left SND (I–IV)	9 wk	Right	Retired
10	Female	50	T1N0M0 oral tongue	No	Right SND (I–IV)	8 wk	Right	Nurse

^a TNM=tumor, nodes, metastasis; SCC=squamous cell carcinoma; MRND=modified radical neck dissection; SND=selective neck dissection.

included in the model. The generalized linear mixed model included a random effect for participant and was used to account for repeated measurements within participants.

Results

The sampling frame consisted of 19 potential participants with neck dissection and suspected ANSD. Four potential participants were unable to be contacted: 1 had pre-existing medical comorbidities that prevented performance of the exercises, 2 had metastatic disease, 1 declined to participate, and 1 had no ANSD upon assessment. The final sample consisted of 10 participants with neck dissection. Baseline characteristics of the individual participants are shown in Table 1. The mean age of the final sample was 59.8 years (range=50–75 years). Eighty percent of the participants were male. Half of the participants were receiving or had previously received adjuvant radiation therapy, with a mean treatment time of 24.2 weeks (range=4 weeks–20 months) from date of surgery to the study assessment date. Two participants

had undergone a bilateral neck dissection. Both of these participants demonstrated only one side that was affected by ANSD, which was subsequently classified as the NDA side. Three participants had neck dissection surgery on their dominant-side shoulder.

EMG Activity

Results of raw EMG activity in smoothed RMS form by muscle group and exercise performed are summarized in Table 2. Data for exercise 6 were collected for only 3 participants, either because of inability to perform the exercise correctly due to pain or inability to maintain the exercise position (4 participants) or because the signals were noisy from either movement artifact (1 participant) or ECG artifact (2 participants). As there was a large amount of missing data for exercise 6, this exercise was excluded from subsequent data analysis.

For the NDA group, upper trapezius muscle EMG activity was highest for exercises 2 and 7, respectively. Middle trapezius muscle EMG activity

was maximized for exercises 2 and 5. Exercises 2 and 5 had the highest EMG activity for combined upper and middle trapezius muscles in the NDA group. In the NDU group, although a similar pattern for upper and middle trapezius muscles was observed, the peak levels of activity were observed in exercises 1 and 5 for both muscle parts. Overall, trapezius muscle activity was greatest in exercises 2, 5, and 1, respectively, for NDA and NDU combined.

The NDA group demonstrated lower levels of EMG activity compared with the NDU group for the upper trapezius muscle in all exercises, with EMG activity for exercises 1 and 7 being statistically significantly lower. Middle trapezius muscle activity was statistically significantly lower for all exercises, other than exercise 7, in the NDA compared with the NDU group.

For accessory scapular muscles in the NDA group, exercises 3 and 4 demonstrated the highest levels of rhomboid major muscle EMG activity, and exercises 1 and 2 were asso-

Table 2.

Raw Electromyographic (EMG) Scapular Muscle Differences by Group and Exercise^a

Muscle Group	Exercise Performed	NDU Group Mean EMG Activity (mV)	NDA Group Mean EMG Activity (mV)	Mean Difference ^b (mV)	95% CI of the Difference
UT	1. Shoulder shrug	0.084	0.054	0.030*	0.008 to 0.051
	2. Overhead press	0.073	0.065	0.008	−0.016 to 0.032
	3. Row standing	0.066	0.054	0.012	−0.010 to 0.033
	4. Row prone	0.057	0.044	0.013	−0.007 to 0.033
	5. Adduction/flexion	0.083	0.063	0.020	−0.004 to 0.044
	6. Wall press-up
	7. Protraction supine	0.078	0.068	0.011*	0.012 to 0.035
MT	1. Shoulder shrug	0.261	0.071	0.190*	0.067 to 0.314
	2. Overhead press	0.235	0.097	0.138*	0.053 to 0.223
	3. Row standing	0.222	0.073	0.149*	0.067 to 0.230
	4. Row prone	0.128	0.054	0.074*	0.024 to 0.125
	5. Adduction/flexion	0.241	0.090	0.151*	0.070 to 0.231
	6. Wall press-up
	7. Protraction supine	0.031	0.041	−0.008	−0.015 to −0.001
RH	1. Shoulder shrug	0.056	0.092	−0.035	−0.075 to 0.004
	2. Overhead press	0.123	0.042	0.082*	0.040 to 0.123
	3. Row standing	0.075	0.110	−0.035	−0.071 to 0.002
	4. Row prone	0.100	0.113	−0.013	−0.063 to 0.036
	5. Adduction/flexion	0.077	0.041	0.035*	0.017 to 0.053
	6. Wall press-up
	7. Protraction supine
SA	1. Shoulder shrug	0.034	0.151	−0.117	−0.332 to 0.099
	2. Overhead press	0.114	0.110	0.004	−0.036 to 0.043
	3. Row standing	0.045	0.062	−0.017	−0.061 to 0.026
	4. Row prone	0.040	0.071	−0.032*	−0.061 to −0.003
	5. Adduction/flexion	0.110	0.101	0.009	−0.013 to 0.031
	6. Wall press-up
	7. Protraction supine	0.059	0.068	−0.008	−0.018 to 0.001

^a UT=upper section of trapezius muscle, MT=middle section of trapezius muscle, RH=rhomboid muscle, SA=serratus anterior muscle, NDU=neck dissection unaffected arm group, NDA=neck dissection affected arm group, 95% CI=95% confidence interval. Ellipsis indicates missing data or data insufficient for analysis.

^b Mean difference=EMG difference of NDU group compared with NDA group. Asterisk indicates statistically significant difference.

ciated with highest levels of serratus anterior muscle activity. Three out of 5 exercises for the rhomboid major muscle in the NDA group had higher levels of EMG activity compared with the NDU group; however, this pattern was the reverse for exercises 2 and 5, with significantly higher rhomboid muscle activity in the NDU group. A similar pattern was observed in the serratus anterior muscle, with higher muscle activity in the NDA group for 4 out of 6 exercises and with muscle activity for exercise 4 being significantly higher in the NDA compared with the NDU group.

Discussion

This is the first study to examine dynamic SEMG activity of scapular

muscles in the neck dissection population, which arguably has greater clinical relevance for rehabilitation purposes than preceding static EMG studies.^{15,16} Although EMG muscle activity is not a measure of strength, strengthening exercises are prescribed to enhance muscle activity because there is association between these outcomes.²³

Both the upper and middle sections of the trapezius muscle in patients affected with ANSD following neck dissection surgery demonstrated less dynamic EMG activity compared with their unaffected side. Patients with radical neck dissection and accessory neurotmesis were excluded, as there is no potential for nerve recovery and trapezius muscle strengthen-

ing exercises, therefore, are physiologically likely to be ineffective.¹³ Reduced trapezius muscle EMG levels in the operated side primarily result from intraoperative nerve injury of the accessory nerve. Post-operative radiation therapy and overall physical deconditioning further compound the trapezius muscle activity loss. However, other factors also may influence the SEMG results found. Soft tissue scarring and fibrosis in the ipsilateral neck region resulting from both neck dissection and radiation therapy may further reduce measured muscle activity in the upper and middle trapezius muscles (which are contained in the lateral neck area). Radiation therapy causes soft tissue fibrosis, which reduces muscle fiber contractility.

Additionally, the tissue composition between the surface electrode and the electrical activity of the muscle under study influences SEMG activity.²⁴ Scar tissue is likely to affect the impedance of the SEMG signal. Although the factors of tissue composition are unavoidable in this patient group, it potentially influences the SEMG differences found between the operated and unaffected sides.

The greater differences in middle trapezius muscle activity, compared with upper trapezius muscle activity, found between the NDA and NDU groups may be related to the surface electrode location used. Many EMG studies report using the insertion points of the spinous process of the seventh cervical vertebra and the angle of the acromion for upper trapezius muscle location.^{18,22,25} However, anatomical studies reveal that these insertion points are those for middle trapezius muscle fibers.^{19,20} This study based electrode placement for trapezius muscle parts on anatomical studies. Thus, the middle trapezius muscle electrode location we utilized was that for upper trapezius muscle in several other studies. These different electrode locations may explain the greater differences in the middle trapezius muscle compared with the upper trapezius muscle found between groups in this study.

Collectively, exercises 2, 5, and 1 demonstrated the highest levels of EMG activity for the upper and middle trapezius muscles of the NDA and NDU groups. These findings suggest that overhead strengthening exercises are likely to more effectively recruit trapezius muscle fibers. These exercises, therefore, should be prioritized in the exercise selection for patients with ANSD, given that the main rehabilitation focus is to maximize trapezius muscle activity to correct the biomechanical

scapular deficit. However, patients with ANSD exhibit restricted active shoulder flexion and abduction¹⁵ because of abnormal scapular biomechanics resulting from trapezius muscle weakness. Therefore, performing exercises in an overhead direction may not always be feasible in this patient group due to regional pain resulting from subacromial impingement and glenohumeral joint restriction. The effect of repeated exercise on muscle activity or pain was not investigated, as the study protocol included one assessment only with 3 repetitions of each exercise. Performing exercises over a longer period may yield different results, not only in terms of muscle activity, but also practicality. Overhead activity exercises may worsen shoulder pain, so caution needs to be used when prescribing exercises into a restricted movement direction. Exercises 1 and 3 are associated with the next highest levels of upper and middle trapezius activity and do not involve movement in an overhead direction. Thus, if patients are reporting pain with exercises 2 and 5, it is suggested that exercises 1 and 3 should be prescribed as an alternative.

The higher EMG activity found in the serratus anterior muscle, and to a lesser extent in the rhomboid accessory muscles, in the NDA group compared with the NDU group was an interesting finding. This finding is suggestive of compensatory muscle activity in the accessory scapular muscles of patients affected with ANSD, in particular the serratus anterior muscle, working to balance the trapezius muscle deficit. The conflicting results for rhomboid muscle activity indicate that its role in ANSD is uncertain. Although the trapezius and serratus anterior muscles often are considered to work as a force couple to control scapular external rotation, direct reciprocal muscle activity does not exist. Both

synergistic and antagonistic activity of the serratus anterior muscle occur.²⁶ This force couple assists the trapezius muscle to laterally rotate the scapula and anchor the scapula onto the ribs; however, it also is antagonistic to the upper trapezius muscle in that it abducts the scapula. A similar conflicting force couple exists with the rhomboid muscle,²⁶ which works synergistically with the trapezius muscle to adduct the scapula, but antagonistically to downwardly rotate it.

Whether this observed increased scapular accessory muscle activity in patients with ANSD should be encouraged or avoided is certainly arguable. Peripheral nerve lesions are linked with central nervous system reorganization, with plasticity mechanisms resulting in either beneficial adaptive changes or deleterious maladaptive changes if abnormal movement patterns are promoted.^{27,28} Knowledge as to the prognosis for accessory nerve recovery is likely to guide rehabilitation decisions related to whether to actively promote serratus anterior and rhomboid muscle activity. For those patients with longer recovery anticipated of the accessory nerve due to greater levels of nerve injury, such as with axonotmesis or neurotmesis, it would seem feasible to encourage accessory muscle use for functional purposes. Promotion of accessory muscle use, particularly the serratus anterior muscle, may aid scapula rotation and subsequently improve glenohumeral abduction, reducing shoulder pain. The challenge is that often the degree of nerve injury is unknown, other than with radical neck dissection when the nerve is severed.

Accessory nerve function following neck dissection can be assessed through the use of continuous intraoperative nerve monitoring. This procedure involves stimulation of

the accessory nerve throughout surgery with measurement of trapezius muscle output. It allows the identification and preservation of the nerve during surgery²⁹ and, importantly, gives an indicator if there are any differences in accessory nerve function between the start and the completion of surgery. Therefore, any patient who demonstrates reduced motor output of the trapezius muscle after neck dissection can be identified and referred for physical therapy management. Participants in this study did not undergo intraoperative accessory nerve monitoring. The presence of abnormal muscle imbalances was established by the demonstrated typical clinical signs (scapular depression, reduced active shoulder abduction, and scapular winging at rest and on active shoulder abduction). The inclusion of intraoperative accessory nerve monitoring would be a useful tool to consider for further study to establish definitive levels of accessory nerve injury, which then could be related to EMG findings.

Exercise order was based on those exercises currently being investigated as part of a randomized controlled study by the authors. Sequence of exercises performed may have affected muscle activity results, as the order of exercises was not randomized. Therefore, there was a possibility of muscle fatigue affecting the muscles both during the latter exercises and in the unaffected arm that was secondarily tested. Raw EMG data comparisons have limitations due to individual anatomical differences such as muscle fiber composition and adipose tissue.³⁰

Muscle activity levels during exercise expressed as a percentage of maximal voluntary contraction (%MVC) typically are utilized as a normalization technique to address this measurement issue. However, if a participant is experiencing a pain-

ful condition, it is likely to reduce the validity of the %MVC normalization method.³⁰ Another commonly used EMG normalization technique is to utilize a submaximal reference voluntary contraction, thereby avoiding the limitations associated with a maximal muscle contraction. A submaximal reference voluntary contraction typically occurs in the mid-range of movement, and in the shoulder, this often is in 125 degrees of shoulder scaption while holding a weight for several seconds.³¹ The feasibility of participants in this study being able to reliably perform this normalization technique is low due to the reduced glenohumeral joint range of flexion and abduction by virtue of having an accessory nerve injury. As such, neither normalization technique was performed. Given that comparisons were within participants, no participants were obese or particularly overweight, and raw data comparison is a more accurate reflection of patient populations who experience a painful condition,²² these comparisons were considered acceptable.

The trapezius is a large and crucial muscle that aids in scapular elevation and lateral rotation to allow normal glenohumeral joint movement. Patients with ANSD demonstrate muscle activity deficits in both upper and middle sections of the trapezius muscle, affecting scapular biomechanics and causing restricted shoulder movement and pain.¹ Physical therapy rehabilitation of patients with ANSD and an intact accessory nerve following neck dissection should include some form of upper and middle trapezius muscle strengthening to maximize trapezius muscle activity. The roles of the serratus anterior and rhomboid major muscles are less clear in relation to exercise prescription. Both nerve recovery stage and potential need to be considered if including accessory

muscle strengthening exercises in scapular rehabilitation.

Conclusion

Lower levels of middle and upper trapezius muscle dynamic EMG activity were demonstrated in patients who have undergone neck dissection surgery and are affected by ANSD compared with their unaffected side. A trend toward higher dynamic serratus anterior muscle activity was evident in the ANSD-affected arm, which may suggest a compensatory accessory muscle strategy. Consideration should be given to scapular muscle activity differences following neck dissection and the potential for regaining accessory nerve function when treating patients with ANSD. Physical therapy in patients after neck dissection surgery is challenging because of the morbidity in treatment of cancer, which places limitations on patients' ability to exercise. It is crucial that exercise prescription be specific to maximize rehabilitation gains and capitalize on recovery processes. Exercises shown in this study to maximize trapezius muscle activity should guide physical therapists' exercise selection and should be used with careful monitoring to avoid any painful symptoms and ensure correct scapular stabilization.

Ms McGarvey, Mr Osmotherly, and Dr Chiarelli provided concept/idea/research design. Ms McGarvey, Dr Hoffman, and Dr Chiarelli provided writing. Ms McGarvey and Dr Hoffman provided data collection and study participants. Ms McGarvey and Mr Osmotherly provided data analysis and project management. Ms McGarvey provided fund procurement. Mr Osmotherly provided facilities/equipment. Mr Osmotherly and Dr Hoffman provided institutional liaisons. Mr Osmotherly, Dr Hoffman, and Dr Chiarelli provided consultation (including review of manuscript before submission).

Ethical approval to conduct this study was granted by the Hunter New England Health Research Ethics Committee and the Univer-

Scapular Muscle Exercises Following Neck Dissection Surgery

sity of Newcastle Human Research Ethics Committee.

DOI: 10.2522/ptj.20120385

References

- van Wilgen CP, Dijkstra PU, van der Laan AM, et al. Shoulder complaints after nerve sparing neck dissections. *Int J Oral Maxillofac Surg*. 2004;33:253-257.
- Hillel AD, Kroll H, Dorman J, Medeiros J. Radical neck dissection: a subjective and objective evaluation of postoperative disability. *J Otolaryngol*. 1989;18:53-61.
- Chepeha DB, Taylor RJ, Chepeha JC, et al. Functional assessment using Constant's Shoulder Scale after modified radical and selective neck dissection. *Head Neck*. 2002;24:432-436.
- Moseley JB, Jobe FW, Pink M, et al. EMG analysis of the scapular muscles during a shoulder rehabilitation program. *Am J Sports Med*. 1992;20:128-134.
- Martins J, Tucci H, Andrade R, et al. Electromyographic amplitude ratio of serratus anterior and upper trapezius muscles during modified push ups and bench press exercises. *J Strength Cond Res*. 2008;22:477-484.
- Sewall GK, Palazzi-Churas KL, Richards GM, et al. Planned postradiotherapy neck dissection: rationale and clinical outcomes. *Laryngoscope*. 2007;117:121-128.
- Lefaix J-L, Delanian S, Vozenin M-C, et al. Striking regression of subcutaneous fibrosis induced by high doses of gamma rays using a combination of pentoxifylline and α -tocopherol: an experimental study. *Int J Radiat Oncol Biol Phys*. 1999;43:839-847.
- Stone HB, Coleman CN, Anscher MS, McBride WH. Effects of radiation on normal tissue: consequences and mechanisms. *Lancet Oncol*. 2003;4:529-536.
- van den Berg MG, Rasmussen-Conrad EL, Gwasara GM, et al. A prospective study on weight loss and energy intake in patients with head and neck cancer, during diagnosis, treatment and revalidation. *Clin Nutr*. 2006;25:765-772.
- Rogers LQ, Courneya KS, Robbins KT, et al. Physical activity and quality of life in head and neck cancer survivors. *Support Care Cancer*. 2006;14:1012-1019.
- McNeely M, Parliament M, Seikaly H, et al. Predictors of adherence to an exercise program for shoulder pain and dysfunction in head and neck cancer survivors. *Support Care Cancer*. 2012;20:515-522.
- McNeely M, Parliament M, Seikaly H, et al. Effect of exercise on upper extremity pain and dysfunction in head and neck cancer survivors. *Cancer*. 2008;113:214-222.
- McGarvey AC, Chiarelli P, Osmotherly PG, Hoffman GR. Physiotherapy for accessory nerve shoulder dysfunction following neck dissection surgery: a literature review. *Head Neck*. 2011;33:274-280.
- Koybasioglu A, Tokcaer AB, Uslu SS, et al. Accessory nerve function after modified radical and lateral neck dissections. *Laryngoscope*. 2000;110:73-77.
- Erisen L, Basel B, Irdesel J, et al. Shoulder function after accessory nerve-sparing neck dissections. *Head Neck*. 2004;26:967-971.
- Orhan KS, Demirel T, Baslo B, et al. Spinal accessory nerve function after neck dissections. *J Laryngol Otol*. 2007;121:44-48.
- Boettcher C, Cathers I, Ginn KA. The role of shoulder muscles is task specific. *J Sci Med Sport*. 2010;13:651-656.
- Boettcher C, Ginn KA, Cathers I. Standard maximum isometric voluntary contraction tests for normalizing shoulder muscle EMG. *J Orthop Res*. 2008;26:1591-1597.
- Mercer SR. Surface electrode placement and upper trapezius. *Adv Physiother*. 2002;4:50-53.
- Johnson G, Bogduk N, Nowitzke A, House D. Anatomy and actions of the trapezius muscle. *Clin Biomech*. 1994;9:44-50.
- Hermens HJ, Freriks B, Disselhorst-Klug C, Rau G. Development of recommendations for SEMG sensors and sensor placement procedures. *J Electromyogr Kinesiol*. 2000;10:361-374.
- Wegner S, Jull G, O'Leary S, Johnston V. The effect of a scapular postural correction strategy on trapezius activity in patients with neck pain. *Man Ther*. 2010;15:562-566.
- Häkkinen K, Komi PV, Alén M. Effect of explosive type strength training on isometric force- and relaxation-time, electromyographic and muscle fibre characteristics of leg extensor muscles. *Acta Physiol Scand*. 1985;125:587-600.
- Giroux B. Comparisons between surface electrodes and intramuscular wire electrodes in isometric and dynamic conditions. *Electromyogr Clin Neurophysiol*. 1990;30:397-405.
- Ekstrom RA, Soderberg GL, Donatelli RA. Normalization procedures using maximum voluntary isometric contractions for the serratus anterior and trapezius muscles during surface EMG analysis. *J Electromyogr Kinesiol*. 2005;15:418-428.
- Sahrmann S. *Diagnosis and Treatment of Movement Impairment Syndromes*. St Louis, MO: Mosby Inc; 2001.
- Navarro X, Vivo M, Valero-Cabre A. Neural plasticity after peripheral nerve injury and regeneration. *Prog Neurobiol*. 2007;82:163-201.
- Coq J, Barr A, Strata F, et al. Peripheral and central changes combine to induce motor behavioural deficits in a moderate repetition task. *Exp Neurol*. 2009;220:234-245.
- Midwinter K, Willatt D. Accessory nerve monitoring and stimulation during neck surgery. *J Laryngol Otol*. 2002;116:272-274.
- Mathiassen SE, Winkel J, Hagg GM. Normalization of surface EMG amplitude from the upper trapezius muscle in ergonomic studies: a review. *J Electromyogr Kinesiol*. 1995;5:197-226.
- Hsu Y, Chen W, Lin H, et al. The effects of taping on scapular kinematics and muscle performance in baseball players with shoulder impingement syndrome. *J Electromyogr Kinesiol*. 2009;19:1092-1099.



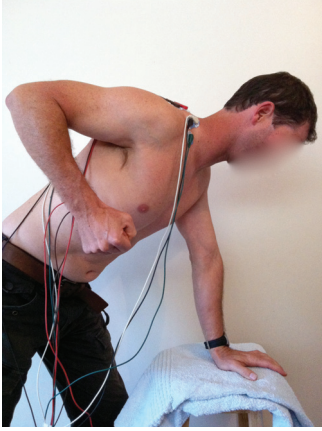
Appendix 1.

Anatomical Landmarks of Scapular Muscles for Electrode Placement and Maximal Voluntary Isometric Contraction (MVIC)

Muscle	Electrode Placement	MVIC
Upper trapezius	3 cm superior to lateral one third clavicle and directed to ligamentum nuchae	Scapula elevation in sitting position. Resistance applied into shoulder depression and cervical spine contralateral flexion.
Middle trapezius	4 cm proximal to acromion toward C7 spinous process	As for upper trapezius muscle.
Rhomboid major	3 cm from junction of middle and lower third of scapula border and T2 spinous process	Prone, head rotated ipsilaterally. Scapula adducted and elevated. Elbow fully flexed, shoulder extended and adducted. Resistance applied into shoulder abduction and depression.
Serratus anterior	Superior aspect eighth rib mid-axillary line directed anteriorly	Supine, shoulder at 90° flexion, elbow fully extended. Resistance applied into shoulder retraction.

Appendix 2.

Dynamic Maneuvers Performed^a



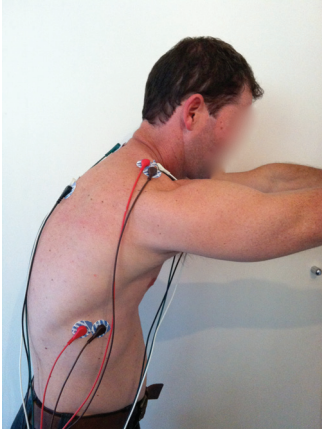
Dynamic Exercise	Muscles Targeted	Exercise Description	
1. Shoulder shrug	Upper trapezius	In standing position, tested arm by side and elbow fully extended, holding dumbbell. Scapula in neutral position of elevation/depression. Elevate scapula to maximum height, maintaining position of elbow and glenohumeral joint, then return to start position.	
2. Overhead press	Upper trapezius	In standing position, shoulder abducted to 90 degrees so humerus is at horizontal level and elbow flexed to 90 degrees, holding dumbbell. Extend elbow fully so weight moves up toward ceiling, then return to start position.	
3. Single-arm row in standing position	Rhomboid major	In standing position, contralateral hand on plinth, and trunk flexed to approximately 45 degrees, with contralateral leg in front in a lunge position. Ipsilateral hand holding dumbbell, with elbow fully extended. Ipsilateral shoulder flexed in line with contralateral knee, holding on to dumbbell with elbow fully extended. Retract scapula and flex elbow, pulling dumbbell toward ipsilateral lower rib region.	

(Continued)

Scapular Muscle Exercises Following Neck Dissection Surgery

Appendix 2.

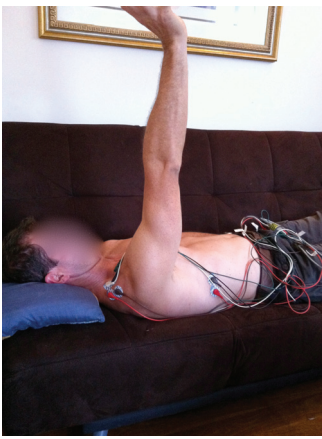
Continued

Dynamic Exercise	Muscles Targeted	Exercise Description	
4. Single-arm row in prone position	Rhomboid major	In prone position, holding dumbbell. Contralateral hand under forehead to maintain neck in neutral position. Ipsilateral glenohumeral joint just clear of plinth. Ipsilateral shoulder in approximately 90 degrees of flexion with elbow fully extended and end-range scapula protraction as gravity allows. Retract scapula and flex elbow, pulling dumbbell toward ipsilateral lower rib region. No shoulder abduction permitted.	
5. Horizontal adduction/flexion	Serratus anterior	In sitting position. Start position is with wrist in line with shoulder and elbow flexed. Raise arm toward midline and upward, combining shoulder adduction and flexion.	
6. Bilateral arm wall press-up	Serratus anterior	Both hands positioned on wall placed shoulder width apart and shoulders flexed to 90 degrees. Start position is full scapula retraction with sternum depressed toward wall, elbows fully extended. End position is maximum scapula protraction, shoulders and elbows remain in starting position.	

(Continued)

Appendix 2.

Continued

Dynamic Exercise	Muscles Targeted	Exercise Description	
7. Scapula protraction in supine position	Serratus anterior	In supine position, shoulder at 90 degrees of flexion, holding dumbbell, elbow fully extended, ipsilateral scapula fully on plinth surface. Protract scapula fully so scapula lifts off plinth, then return to starting position. Shoulder and elbow remain in same position as at the start. No trunk rotation permitted.	

^a Photographs show electrode placement for each exercise.

Physical Therapy

Journal of the American Physical Therapy Association and



Scapular Muscle Exercises Following Neck Dissection Surgery for Head and Neck Cancer: A Comparative Electromyographic Study

Aoife C. McGarvey, Peter Grant Osmotherly, Gary R. Hoffman and Pauline E. Chiarelli
PHYS THER. 2013; 93:786-797.
Originally published online February 21, 2013
doi: 10.2522/ptj.20120385

References

This article cites 30 articles, 1 of which you can access for free at:

<http://ptjournal.apta.org/content/93/6/786#BIBL>

Subscription Information

<http://ptjournal.apta.org/subscriptions/>

Permissions and Reprints

<http://ptjournal.apta.org/site/misc/terms.xhtml>

Information for Authors

<http://ptjournal.apta.org/site/misc/ifora.xhtml>
